

# Dual Oblique Skin Incisions for Proximal Median Nerve Entrapment

William B. Ericson, Jr., MD, FACS, FAAOS

Ericson Hand and Nerve Center, Seattle, Washington, USA, 425-776-4444, www.ericsonhand.com

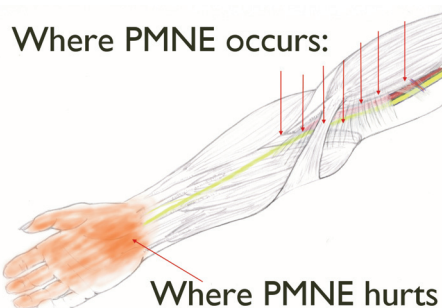
## INTRODUCTION

Proximal Median Nerve Entrapment (PMNE) is a challenging diagnosis for many reasons: inherently vague complaints, subtle physical exam findings that are not well-described, electrodiagnostic tests are unreliable to confirm the diagnosis, and the results of surgery can be unpredictable. The anatomy around the proximal median nerve adds to the complexity of both the diagnosis and treatment, as there are multiple anatomic features in region of the elbow with the potential to cause compression of the nerve. It has been recommended that surgical decompression of the proximal median nerve, if considered, address each possible area of compression (1) (2) (3). Large incisions about the elbow permit full visualization of pertinent anatomy, but can cause seriously disfiguring scars. This paper describes the use of two small incisions which allow safe visualization of the entire proximal median nerve, with cosmetically acceptable scars.

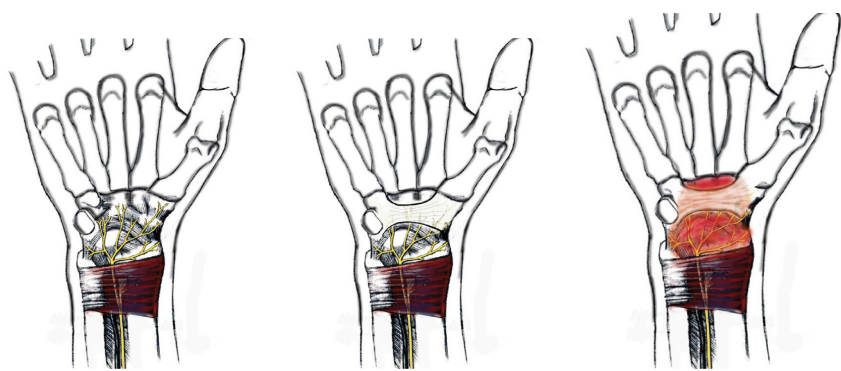
## BACKGROUND

PMNE presents with complaints of "hand pain" or "wrist pain", and "hand weakness." The pain is in the distribution of the distal median nerve (ie, hand/wrist, in particular the terminal branch of the Anterior Interosseous Nerve (AIN), which innervates the volar carpus) and the pain is provoked by activities involving repetitive/sustained pronation, such as typing, writing, driving, and use of a cellphone (4). The "hand weakness" is from isolated weakness of the FPL and FDP IF, which are innervated by the AIN. The physical finding of AIN weakness localizes the site of compression at or proximal to the arch of the superficial flexors.

From proximal to distal, the sites of potential compression proximal median nerve are as follows: the Arcade of Struthers, the Fascia of Struthers, the Ligament of Struthers, the proximal fascial edge of the pronator teres muscle, the lacertus fibrosus, the deep fascia of the ulnar origin of the pronator teres muscle, the deep fascia of the humeral origin pronator teres muscle, the pronator teres muscle itself, and the fascia of the arch of the superficial flexors.



**Figure 1:** There are multiple sites where the proximal median nerve can be compressed. Mild compression of the proximal median nerve causes pain in the distribution of the median nerve, ie, hand/wrist.

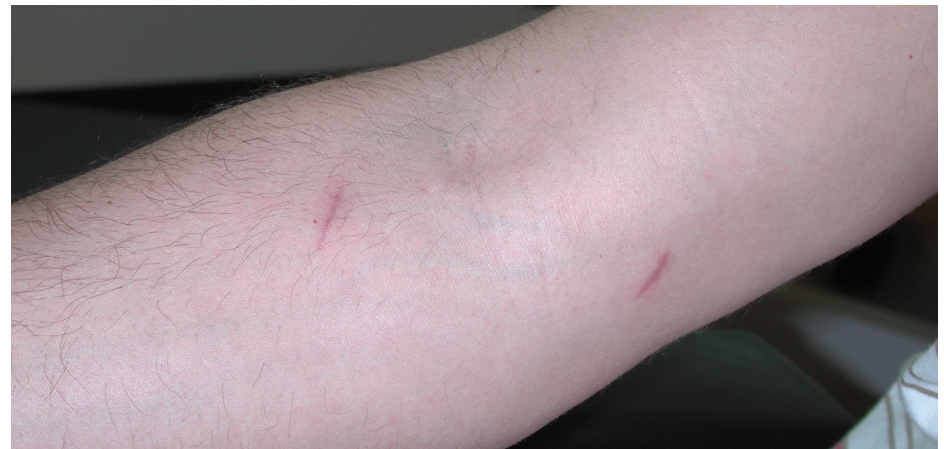

**Figure 2:** Why PMNE hurts in the wrist: 1) The terminal branch of the AIN is a sensory nerve that innervates the carpus, 2) which is deep to the carpal tunnel, and 3) compression of the AIN proximally causes referred pain in the wrist/carpal tunnel.

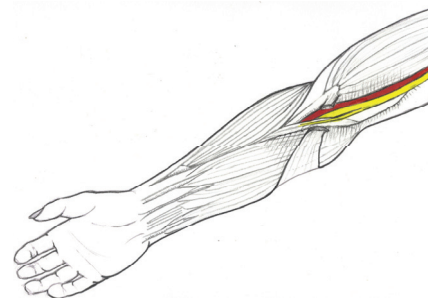
On physical exam, these patients have isolated weakness of the FPL and FDP IF, prompt (less than 60 seconds) numbness in the hand with resisted pronation of the forearm (elbow flexed 90 degrees, forearm fully pronated, against firm resistance), and prompt (less than 60 seconds) numbness in the hand with palpation along the median nerve above and below the elbow. Electrodiagnostic studies, even if they include assessment of the FPL and PQ, are almost always normal.

## TECHNIQUE

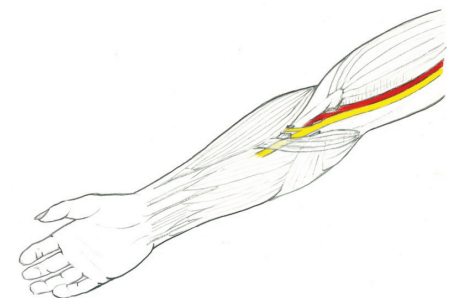
The interval between the flexors and extensors is identified by palpation. The distal incision is 2.5cm long, oblique, centered over the median nerve, starting 3cm distal to the flexion crease of the elbow. The medial epicondyle is identified by palpation. The proximal incision is 2cm long, oblique, centered over the median nerve, ending ~3cm proximal to the medial humeral epicondyle. Under general anesthesia, the arm is exanguinated by gravity and a tourniquet inflated. Skin incisions are completed and injected with 0.25% bupivacaine. Thin, narrow retractors are used for exposure. A loupes-mounted headlight (Zeiss) is used for illumination of the surgical field. An assistant with strong arms, excellent stamina, and the ability to hold quite still is particularly helpful. The median nerve is identified proximally and followed distally, with release of any fascia in contact with the nerve. The incisions are closed with absorbable monofilament sutures and steristrips placed. Tourniquet time is approximately 20 minutes in the average size arm with no unusual anatomic variations.



**Figure 3:** Dual oblique incisions at 2 months following surgery for PMNE.



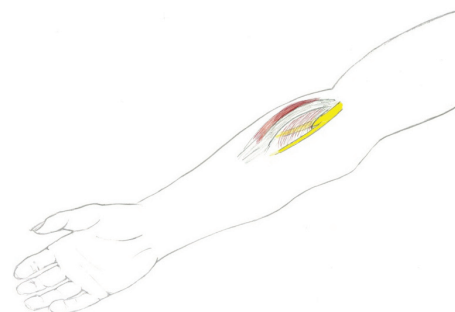
**Figure 4:** Superficial fascia divided (fascia of Struthers, lacertus fibrosus)



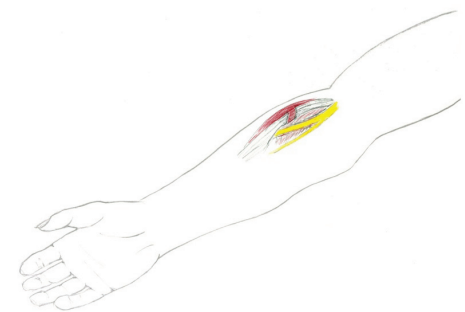
**Figure 5:** Deep fascia divided (fascia of ulnar origin of pronator teres, fascia of arch of superficial flexors)

## RESULTS

The author has had no problem visualizing pertinent anatomy, and has had no major complications related to scar appearance, infection, or injury to nerves or blood vessels using this technique in several hundred cases. All patients have immediate return of the strength of the FPL and FDP IF in the recovery room, and the referred pain to the wrist is also relieved in the recovery room. In addition, the anterior forearm incision is utilized for concurrent release of the radial tunnel simultaneously, if indicated.



**Figure 6:** To release the radial tunnel through the same anterior forearm incision, the sensory branch of the radial nerve is identified and followed proximally.



**Figure 7:** The fascia of the supinator superficial to the posterior interosseous nerve is cut, and a transverse tenotomy is made through the common extensor fascia.

## DISCUSSION

Other authors have described one large incision (3), two linear incisions (5), a transverse incision (6), and endoscopic release (7). The large incisions can widen several centimeters. The transverse incision is not disfiguring, but can make full exposure of the nerve in the forearm more difficult. Endoscopic release of the median nerve offers no advantage over the incisions this author recommends, and is inherently risky, given the anatomic variations and complexity of the forearm.

When considering treatment options for proximal median nerve entrapment, hesitation regarding surgical intervention may be reinforced because of the surgeon's concerns regarding the wide exposure needed for visualization of all sites of possible compression, and the likelihood of an unsightly scar. Small, dual oblique incisions allow adequate exposure of relevant anatomy and produce cosmetically acceptable scars. This simplified technique does not require endoscopy equipment or supplies, nor is there any postoperative casting, splinting, or therapy. The distal incision can also be used to release the radial tunnel, with similar benefits.

## REFERENCES

1. Szabo RM. Entrapment and compression neuropathies. In Green DP, Hotchkiss RN, Pederson WC, Editors. Green's Operative Hand Surgery. 4th ed. Philadelphia: Churchill Livingstone, 1999.
2. Szabo RM, Koo JT. Compression Neuropathies of the Median Nerve. In Slutsky DJ, Hentz VR, Editors. Peripheral Nerve Surgery: Practical Applications in the Upper Extremity. Philadelphia: Churchill Livingstone Elsevier, 2006.
3. Spinner M. Injuries to the major branches of Peripheral Nerves of the Forearm. Philadelphia, WB Saunders, 1978.
4. Ericson WB. Diagnosis and Treatment of Median Nerve Entrapment in the Forearm. Poster presentation at the ASSH Annual Meeting, NYC, 2004.
5. Gainor BJ. Modified exposure for pronator syndrome decompression: a preliminary experience. *Orthopedics*. 1993 Dec; 16(12):1329-31.
6. Tsai TM, Syed SA. A transverse skin incision for decompression of pronator teres syndrome. *J Hand Surg Br*. 1994 Feb; 19(1):40-2.
7. Hoffman R. Minimally Invasive and Endoscopic Techniques in Peripheral Nerve Surgery of the Hand and Forearm. In Siemionow MZ, Editor. New Techniques in Tissue Surgery. London: Springer-Verlag, 2006.